

PERIOPERATIVE MANAGEMENT OF CONN'S SYNDROME (A Case Report)

Dr. Mohd. Ajmi¹, Dr. P. Mandal²

1. Consultant & Chairman of Surgical Disciplines

2. Sr. Specialist, Dept. of Anaesthesia & ICU
Armed Forces Hospital, Kuwait (AFHK)

Correspondence: Dr. P.Mandal; panchanan@hotmail.com

About the Author: Medical graduation is from Kuwait University. Completed postgraduation in general surgery and specialized in Vascular surgery from Germany. Special interest is in bariatric surgery but loves to handle challenging surgical cases judiciously with humane touch and sincerity.



Introduction

Conn's syndrome or primary hyperaldosteronism is a disease of the adrenal gland involving excess production of aldosterone from zona glomerulosa. It can also be caused by adrenal tumours or an enlarged gland due to hyperplasia. Conn's syndrome is important because it is a surgically curable cause of secondary hypertension. It accounts for less than one percent¹⁻³ of all cases of hypertension. It is more common in females than males (2.5:1 ratio). It can occur at any age but most common when a person is in their 30s and 40s. The majority of cases are sporadic but one hereditary cause has been identified. Aldosterone has direct effects on the vasculature and has been associated with vascular smooth muscle cell hypertrophy, endothelial dysfunction, cardiac fibrosis, proteinuria, and renal vascular injury⁴.

Here we present the successful perioperative anaesthetic management of an interesting and rather rare case of adrenal tumour with Conn's syndrome whose preoperative blood pressure was controlled with four antihypertensives including aldactone which is a specific antagonist to aldosterone³. Intraoperative hypertensive peaks were managed with sevoflurane and remifentanyl which was proved to be a good hypotensive technique^{5,6} in non-adrenal surgical procedures.

Key words:

Conn's syndrome: aldosterone. Anaesthesia: general.
Anaesthetics: sevoflurane, remifentanyl.

Case History

A 51 years old lady presented to her physician with complaints of chest pain, weakness and headache one month ago. At that time she was found to have severe hypertension with blood pressure 170/110 mmHg. Serum creatinine level was 56 μ mol/L, blood urea (BUN) was 3mmol/L, serum sodium/potassium level was 146/2.5 mmol/L, renin was 4.1 NG/L (N= 13.6 – 70) and aldosterone was 2168 pmol/L (N= 110-800). Hypertension was gradually controlled with amlodipine 5mg, losartan potassium 50mg, metoprolol 50mg daily. Serum potassium level was corrected to normal range by supplemental potassium chloride therapy. Subsequently MRI abdomen showed a well defined 1 cm x 1.5 cm mass in the right supra-renal gland (Fig.1 & Fig. 2). At this point patient was referred to surgical team for further management. Oral spironolactone (aldactone) 50mg twice daily for five days was added upon her existing antihypertensive drugs as antagonist to high level of aldosterone. Patient was then posted for laparoscopic transperitoneal right adrenalectomy under general anaesthesia.

During preoperative evaluation her general physical examination revealed: body weight 75 Kgs, heart rate (HR) 76/min., blood pressure 150/90 mmHg without any anaemia, generalized oedema or engorged neck veins. She had no respiratory problem and no abnormality was detected on chest examination. Routine preoperative investigations revealed Hb-14.2 gms%, TLC-8000/cmm, Hct-45%, BUN-4.4 mmol/L, serum creatinine-76 μ mol/L, serum Na/K-140/4.2 mmol/L with normal 12 lead ECG and chest X-ray (Fig. 3).

Patient was premedicated orally with midazolam 7.5 mg one dose at previous night and 2nd dose along with all the antihypertensives including aldactone one hour before induction of anaesthesia. On arrival into the operation theatre basic monitoring devices were attached, basal parameters were noted and then venous cannulation was performed for fluid and drug therapy. Anaesthesia was induced with remifentanyl 100 μ g, diprivan 175 mg and intubation was facilitated with cisatracurium (Nimbex®) 1.5 mg/kg. After intubation anaesthesia was maintained with 50% N₂O in O₂, sevoflurane(0.6–2%), infusion of remifentanyl at an average rate of 250 μ g/hour and nimbeX 12 mg/hour along with intermittent positive pressure respiration to maintain normocarbida throughout the procedure. Monitoring consisted of continuous ECG, HR, IBP, CVP, SPO₂, ETCO₂, FiO₂, PAW, blood loss and urine output.

Right adrenalectomy was performed after localizing the adrenal mass laparoscopically in left semilateral position. The procedure lasted for 150 minutes. The drug infusions were stopped in such a time that there was no need of administration of reversal agents to resume spontaneous respiration. After observing adequate tidal volume and muscle power patient was extubated on the table and shifted to ICU for continuous monitoring and further management while receiving O₂ by face mask. In the intraoperative period patient received IV fluids 2200 ml, blood loss was minimal and urine output was 1000 ml. Just before total devascularization of the gland 200 mg hydrocortisone bolus was given and 100 mg every six hours was repeated to prevent any adrenal crisis in the postoperative period. With this patient's haemodynamic parameters were maintained very well without episode of hypertension and hypotension or adrenal crisis at any time.

In the ICU she received analgesic; pethidine 75 mg initially IM and then 10-20 mg/hour as infusion. IV fluid was administered 100 ml/hour. Every six hours her serum sodium/potassium levels were measured and 80 mmol of KCL was supplemented in next 16 hours postoperative period because her 1st postoperative serum potassium level was 3.2 mmol/L. Serum sodium level was normal. Subsequent serum potassium levels were within normal range. All antihypertensive drugs including aldactone were continued from morning of 1st postoperative day and the patient was shifted to ward for further management.

Discussion

Apart from hypertension the associated cardiac problems expected with Conn's syndrome are; left ventricular hypertrophy⁷⁻⁹, increased left ventricular dimension index⁸ represents a detrimental outcome since it is associated with increased morbidity and mortality. For similar elevation of blood pressure the severity and type of LVH vary considerably in relation to several factors. Compelling evidence suggests that both the renin-angiotensin system (RAS) and the aldosterone excess play an important role in the pathogenesis of LVH⁷, since experimentally angiotensin II has been found to cause myocardial cells hypertrophy and/or hyperplasia and excess aldosterone has been related to extracellular matrix and collagen deposition and therefore to myocardial fibrosis⁷. The other problems are hypernatraemia with hypokalaemia², intravascular volume depletion and abnormal renal functions⁴. Fortunately in this patient none of these findings were present in the immediate preoperative period.

As there is hardly any literature report¹⁰ describing anaesthetic management of Conn's syndrome in particular, patient was managed in the line of secondary hypertension due to adrenal tumour.

Meticulous management of haemodynamics without gross fluctuation in its parameters, appropriate IV fluid therapy and prevention of adrenal crisis in the perioperative period were our main concern for this case. Remifentanil was chosen as analgesic as in higher doses it can control high blood pressure during intraoperative period^{5,6} and we were experienced with it. This patient showed hypertension in the intraoperative period (upto 150/105 mmHg) 3 - 4 times although she was on oral aldosterone antagonist aldactone¹¹ along with cardioselective beta-blocker (metoprolol), angiotensin receptor blocker (losartan potassium) plus calcium channel blocker (amlodipin). Those peaks were managed successfully by increasing doses of remifentanil along with sevoflurane which is also a good vasodilator. This type of hypertensive peaks are quite common in cases of Conn's syndrome even after thorough preoperative blood pressure control as reported by Gockel I et al in their series¹². The other hypotensive techniques possible are deep isoflurane anaesthesia¹³⁻¹⁶, IV infusion of labetalol¹⁷, sodium nitroprusside (SNP)¹⁸⁻²², nitroglycerin (NTG)¹⁸⁻²², adenosine^{18,19}, prostaglandin E1²³, trimetaphan (arfonad)²⁴ pretreated with either beta-blocker²⁵ or captopril²⁵⁻²⁶. Each agent has its own advantage or disadvantage either from technique point of view or from its potency and/or promptness (SNP vs NTG), adverse effects on coronary (isoflurane), organ and tissue circulation producing metabolic acidosis, tachyphylaxis (SNP) or rebound hypertension or inadvertent profound hypotension (SNP). Postoperative adrenal crisis was avoided by adequate fluid plus supplemental IV hydrocortisone therapy. Hence it may be recommended that combined remifentanil and sevoflurane anaesthesia may be administered in patient of Conn's syndrome for removal of pathological adrenal gland in absence of IV aldactone preparation.

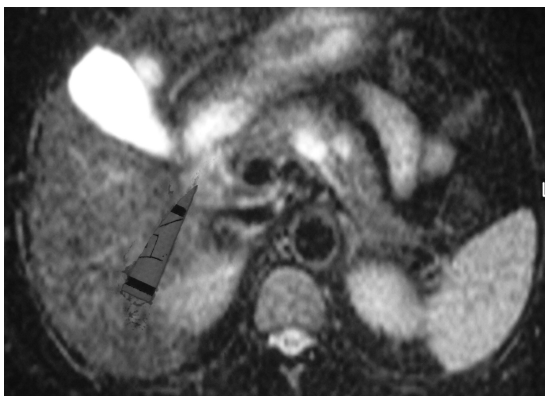


Figure: 1.

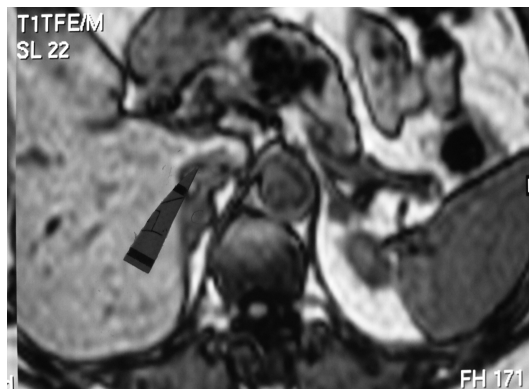

Figure: 2.

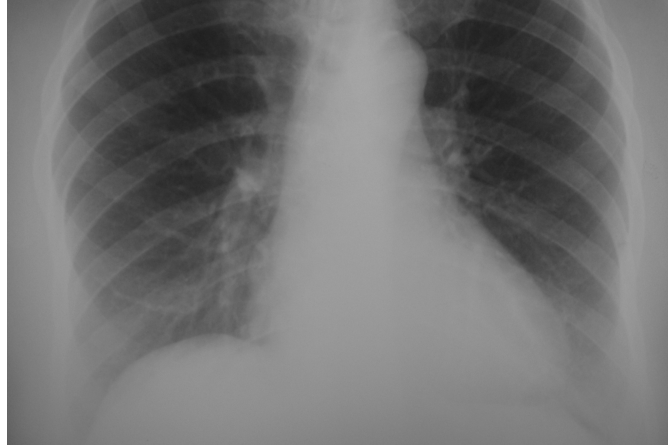

Figure: 3.

References

1. Morris J Brown, Ruth V Hopper. Calcium-channel blockade can mask the diagnosis of Conn's syndrome. *Postgrad Med J* 1999;75(April): 235-236.
2. Wheeler MH and Harris DA. Diagnosis and management of primary aldosteronism. *World J Surg.*2003;27(6):627-31.
3. Mattsson C,Young WF Jr. Primary aldosteronism: diagnostic and treatment strategies. *Nat Clin Pract Nephrol.* 2006;2(4):198-208.
4. Fritsch Neves M and Schiffrin EL. Aldosterone: a risk factor for vascular disease. *Curr Hypertens Rep.* 2003;5(1):59-65.
5. Edwin B; Raeder I; Trondsen E; Kaaresen R; Buanes T. Outpatient laparoscopic adrenalectomy in patients with Conn's syndrome. *Surg Endosc.* 2001; 15(6):589-91.
6. Mandal P. Hypotensive Anaesthesia with Remifentanil for FESS procedure. *J.An aesth.Clin. Pharmacol.*2003;19:411-15.
7. Pessina AC, Sacchetto A and Rossi GP. Left ventricular anatomy and function in primary aldosteronism and renovascular hypertension. *Adv Exp Med Biol.*1997;432:63-69.
8. Suzuki T,Abe H, Nagata S, Saitoh F et al. Left ventricular structural characteristics in unilateral renovascular hypertension and primary aldosteronism. *Am J Cardiol.*1988 Dec 1;62(17):1224-7.
9. Rossi GP, Sacchetto A,Visentin P et al. Changes in left ventricular anatomy and function in hypertension and primary aldosteronism. *Hypertension.* 1996 May;27(5):1039-45.
- 10.Lertakyamanee N, Somprakit P and Buranakijaroen P et al. Anesthesia and laparoscopic adrenalectomy for primary aldosteronism. *J Med Assoc Thai.* 2001; 84(6):798-803.
- 11.Quinkler M, Reincke M. Modern pharmacological aspects of hyperaldosteronism therapy. *Internist (Berlin).* 2006 Sep;47(9): 953-959.

12. Gockel I, Heintz A, Kentner R and Werner C et al. Changing pattern of the intraoperative blood pressure during endoscopic adrenalectomy in patients with Conn's syndrome. *Surg Endosc.* 2005; 19(11):1491-97.
13. P. Mandal. Isoflurane anaesthesia for functional endoscopic sinus surgery (FESS). *Ind.J. Anaesth.* (2003);47:37.
14. Maktabi M, Warner D, Sokoll M, Boarini D, Adolphson A, Speed T, Kassell N. Comparison of nitroprusside, nitroglycerin, and deep isoflurane anesthesia for induced hypotension. *Neurosurgery.* 1986 Sep;19(3):350-5.
15. Bernard JM, Pinaud M, Ganansia MF et al. Systemic haemodynamic and metabolic effects of deliberate hypotension with isoflurane anaesthesia or sodium nitroprusside during total hip arthroplasty. *Can J Anaesth.* 1987 Mar;34(2):135-40.
16. Fujita Y, Habazettl H, Corso CO, Messmer K, Yada T. Comparative effects of hypotension due to isoflurane, nitroglycerin, and adenosine on subendocardial microcirculation: observation of the in situ beating swine heart under critical stenosis. *Anesthesiology.* 1997 Aug;87(2):343-53.
17. Gurevich B, Artru AA, Geva D, Gurman G, Shapira Y. Labetalol-induced hypotension decreases blood loss during uncontrolled hemorrhage. *Resuscitation.* 1998 Jul;38(1):25-32.
18. Norlen K. Central and regional haemodynamics during controlled hypotension produced by adenosine, sodium nitroprusside and nitroglycerin. *Studies in the pig. Br J Anaesth.* 1988 Aug;61(2):186-93.
19. Lagerkranser M, Sollevi A, Irestedt L, Tidgren B, Andreen M. Renin release during controlled hypotension with sodium nitroprusside, nitroglycerin and adenosine: a comparative study in the dog. *Acta Anaesthesiol Scand.* 1985 Jan;29(1):45-9.
20. Flaherty JT, Magee PA, Gardner TL, Potter A, MacAllister NP. Comparison of intravenous nitroglycerin and sodium nitroprusside for treatment of acute hypertension developing after coronary artery bypass surgery. *Circulation.* 1982 Jun;65(6):1072-7.
21. Endrich B, Franke N, Peter K, Messmer K. Induced hypotension: action of sodium nitroprusside and nitroglycerin on the microcirculation. A micropuncture investigation. *Anesthesiology.* 1987 May;66(5):605-13.
22. Yaster M, Simmons RS, Tolo VT, Pepple JM, Wetzel RC, Rogers MC. A comparison of nitroglycerin and nitroprusside for inducing hypotension in children: a double-blind study. *Anesthesiology.* 1986 Aug;65(2):175-9.

23. Kimura H, Kohyama A. Effects of deliberate hypotension on the ischemic heart during isoflurane anesthesia--a comparison of prostaglandin E1 and sodium nitroprusside. *Masui*. 1992 Sep;41(9):1397-405.
24. Vazeery AK, Aspelund K, Ahlgren I. Deliberate arterial hypotension in plastic surgery for the reduction of hypertrophic breast: a critical appraisal of surgical ischaemia and haemodynamic changes during sodium nitroprusside infusion. *Scand J Plast Reconstr Surg*. 1980;14(2):133-40.
25. Pasch T, Kleierl-Lindner C, Gotz H, Pichl J. Rebound hypertension after controlled hypotension and its prevention by captopril. *Anaesthesist*. 1986 ;35(2):66-72.
26. Porter SS, Asher M, Fox DK. Comparison of intravenous nitroprusside, nitroprusside-captopril, and nitroglycerin for deliberate hypotension during posterior spine fusion in adults. *J Clin Anesth*. 1988;1(2):87-95.