



Use of Greenfield Filter to Prevent Pulmonary Embolism: A Case Report

Kundan Sandugir Gosavi¹, Aniruddha Nirkhi¹, Ganesh Pandurang Bhong¹, Debashish Giri²

1. Lecturer, 2. Senior Resident

Department of Anaesthesia, Grant medical college, Mumbai.

Corresponding Author: Dr. Kundan Sandugir Gosavi (kundangiri@rediffmail.com)

About the Author: Dr. Kundan Sandugir Gosavi did his post graduation in Anaesthesiology from Grant medical college, Sir J J Hospital, Mumbai University in May 2007. At present he is working as an assistant professor (Lecturer) at Grant medical college, Mumbai only. His areas of interest are intensive care, epidural- pain management and teaching.



Abstract: A 45 year male operated for meningioma developed breathlessness on 6th day after surgery and was found to have pulmonary embolism due to DVT in right leg. Despite of being on anticoagulants, patient developed thrombosis in left leg too. Fortunately we had placed a Greenfield filter in inferior vena cava; else a single embolus could have been fatal. Follow up of patient for 6 months showed resolution of thrombus with no filter related complications.

Case Report: This 45 year male was admitted to the hospital with history of giddiness and complex partial seizures for 6 months. Patient was non hypertensive, non diabetic with no history of hyperlipidemia, smoking, bed ridden state, stroke, ischemic heart disease or peripheral vascular disease. There was no history of any thrombotic disorder in family. There were no signs of deep venous thrombosis. Homan's and Pratt's sign were negative. Patient's Glasgow coma scale was 15/15 with no cranial nerve dysfunction. No apparent sensory or motor neuro-deficit was present. No significant abnormality in blood investigations. MRI scan revealed a meningioma of 3cmx3.2cmx3.0 cm in left temporal region (ASA Grade1).

Patient was posted for excision of meningioma with adequate starvation hours, informed consent and standard monitoring (ECG, SPO₂, EtCO₂, NIBP and CVP using cavafix® in right antecubital, urine output and temperature).

Standard protocol of induction and intubation was followed using propofol, fentanyl and rocuronium. Anaesthesia was maintained on circle absorber with N₂O +O₂ and isoflurane 1.0 mac. Surgery was uneventful and patient was extubated after reversal with neostigmine. Total duration of anaesthesia (induction to extubation) was 7 hours and 15 mins.

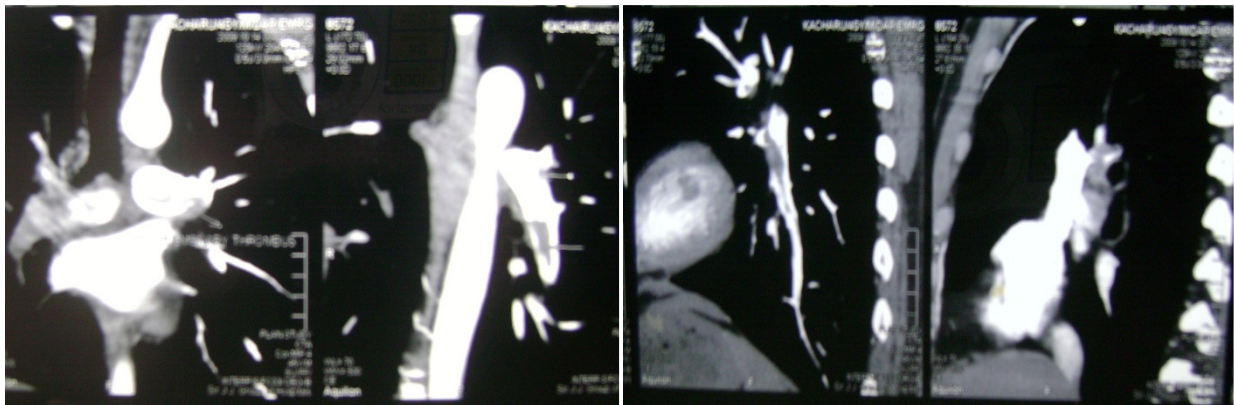
After surgery, patient was shifted to the intensive care unit. Two consecutive arterial blood gas reports (ABG) taken 12 hrs apart as a routine procedure, were within normal limits (PO_2 135.3 and 114.2 mmHg with PCO_2 40.0 and 38.5 respectively) and patient was shifted to the ward after 24 hrs. Patient did well for 5 days.

On 5th day he started having mild cough with greenish expectoration. On auscultation, he had bilateral ronchi more in left apical and interscapular area. He was given antibiotics and salbutamol inhalation which provided him some relief. Very next morning patient started complaining mild breathlessness and right sided chest pain and palpitations. An emergency ECG done revealed no significant finding except tachycardia. Meanwhile, patient also started complaining leg pain. On examination, he had calf tenderness with mild oedema on left leg.

Patient was immediately subjected to lower limb venous Doppler which showed deep venous thrombosis in left external iliac, superficial femoral vein and deep femoral veins, common iliac veins and popliteal veins. Anterior tibial vein & posterior tibial vein had normal flow and respiratory phasic movements.

A blood sample was obtained for protein c, protein s, serum homocysteine and antithrombin levels which came out to be normal later on. Prothrombin time (13.5/11.4 sec), Activated partial thromboplastin time (APTT) (38 sec) & INR (1.20) were normal while platelet count was 149000/ml.

Patients CT angiogram revealed significant left pulmonary artery blockade, complete right pulmonary artery blockade with formation of saddle thrombus. While 2-D echo showed dilated right atrium (29 mm) and right ventricle, rest of the parameters were within normal limits.



CT- ANGIOGRAM SHOWING RIGHT AND LEFT PULMONARY ARTERY THROMBOSIS

ABG analysis done showed PO_2 as 70.9 mmHg, PCO_2 35.9 mmHg, SPO_2 96.5%, with pH of 7.41.

Patient was shifted to the critical care unit and was put on:

- O_2 by venti-mask with 40% FiO_2 .



- Propped up position and chest physiotherapy.
- Inj. Heparin 80 IU/kg (6000 units) bolus followed by 20 IU/kg/ hour (1000 IU) infusion with aim to maintain APTT > 1- 1.5 times the normal.
- Antibiotics- amoxicillin+ clavulinate, 625mg bid.
- I.V. fluids- 40 ml/hour.

ABG after 12 hrs was: PO₂- 124.1 mmHg, PCO₂- 38.7 with APTT 80 sec. APTT was done every 6 hourly for 2 days and ABG 12 hourly. 24 hours after starting heparin we planned putting an IVC filter.

Under all aseptic precautions and local anaesthesia (2% Lignocaine) right femoral artery and femoral vein was canalsed. Under the fluoroscopic guidance, renal veins were localised below the lower border of L1 vertebra. Using ALN delivery system, a Greenfield filter was placed in one space below the renal veins. Inj. Heparin 5000 every 6 hrs was continued as it was before. After 48 hrs patient was started with inj. Enoxaparin (low molecular weight heparin, LMWH) 0.6 ml (subcutaneous) every 12 hrs and was observed in critical care unit. Patient was shifted to the ward after this and did well. Patient received limb elevation, limb exercises and chest physiotherapy along with compression stockings for both legs.

On the 8th day after procedure, Venous Doppler done for follow-up showed normal calibre of left external iliac and good wall to wall flow, with partial recanalisation of the thrombus in common femoral vein. Thrombus in popliteal vein was still there. We started tablet Warfarin 5 mg OD and stopped the LMWH gradually.

After 3 days mild swelling of right leg for which we repeated the Doppler and had following surprising findings: A hypoechoic thrombus in bilateral common femoral vein and deep femoral vein, superficial femoral vein, popliteal vein. On right side it was extending into great saphenous vein, subcutaneous oedema on both sides with more on right side. Flow in inferior vena cava and bilateral common iliac veins were normal. APTT done on same day was 44 sec with PT and INR 2.0 and 2.2. Therefore, the dose of Warfarin was increased to 10 mg daily. Physiotherapy and limb exercises were continued. A Doppler repeated after 7 days showed partial recanalisation of thrombi on both sides. Patient was discharged from hospital after this. Patient was followed up for 6 months showed resolution of almost all the thrombi and had no filter related complications.

Discussion: Deep vein thrombosis is not an uncommon entity in neurosurgery. Before the advent of filter in 1969 surgical femoral ligation or inferior vena cava clipping was mainstay of prevention of pulmonary embolism in cases of venous thromboembolism¹. Now the efficacy and safety of inferior vena cava filters to prevent pulmonary embolism has been largely established² and placement may be performed via minimally invasive interventional radiologic techniques³. Failure of standard antithrombotic treatment is a recognized problem among patients with coexistent cancer⁴. Cancer patients are prone for recurrent thrombosis which can occur in previously non affected limb too⁵.

Anticoagulant failure is a consequence of prothrombotic forces being strong to be suppressed by routine treatment. Elevations in fibrinopeptide A and fibrinogen fragment B β 15-42;



decreased activated partial thromboplastin time and increased fibrinopeptide A levels play an important role in DVT⁶. Meningiomas seem to carry the highest risk of DVT of all intracranial tumors⁷. Patient of brain neoplasm with thrombotic problems have been found to inhibit plasmin, enhance release of thromboplastin, and increase pro-coagulant and platelet aggregatory activity⁸. Sawaya, et al⁹ found that total fibrinolytic activity was reduced in patients with malignant brain tumours. Plasminogen and plasmin inhibitor levels did not show significant changes, but tissue plasminogen activator was low and plasminogen activator inhibitor-1 levels were high in a large proportion of patients.

Douketis et al¹⁰ found that anticoagulant failure was twice as likely when the presenting thrombosis extended from the femoral vein into the pelvis. However, they also found no difference in early recurrence of deep venous thrombosis between patients treated with intravenous unfractionated heparin and those treated with subcutaneous low-molecular-weight heparin. Also, it has been demonstrated that both unfractionated and low-molecular-weight heparin is that they only weakly inhibit thrombin that is bound to fibrin. At the thrombus-blood interface, thrombin is still able to clot fibrinogen¹¹.

In this case, presence of meningioma, history of a long surgery, general anaesthesia and stay in ICU, all of them leading to prolonged immobilisation and hyper-coagulability were present. Pulmonary embolism at times can manifest in dramatic way or may even remain asymptomatic¹². In our case basic investigations like x-ray chest, ABG analysis and ECG showed no significant deviation from normal. Also it seems that intermittent compression stockings and passive exercises may not be sufficient to prevent venous thrombosis and even a single episode of breathlessness should be taken seriously in such cases. Early use of thrombolytic therapy for acute pulmonary embolism accelerates resolution of angiographic and lung scan abnormalities, and pulmonary hypertension rapidly resolves when compared to heparin therapy¹².

Thrombolysis was not possible here because of history of surgery 6 days back. In such cases IVC filter can serve as an effective 'bridge' to anticoagulation therapy until venous thromboembolism prophylaxis can be initiated^{3,13}. But, as the thrombosis was very extensive and patient already had symptoms of pulmonary embolism we decided to start the anticoagulation immediately. Vena caval filters can be considered in patients with recent (within 1 month) or existing venous thrombosis in whom anticoagulation is contraindicated¹⁴. In this case, decision to put an inferior vena cava filter was based on the fact that patient's only one pulmonary artery was patent and only one more episode of embolism could have ceased the circulation. We were also impressed by the work of Jon R. Cohen and colleague¹⁵ who used inferior vena cava filter as a primary treatment of thrombo-embolism without a great morbidity. Whether to continue anticoagulants or not is controversial. We preferred switching to low molecular weight heparin in post filter insertion period because of its easy schedule but David W. and colleagues¹⁶ in their study on this issue concluded that all patients appear to benefit from short term or long term Warfarin therapy and the contraindications are self limited. Again, this decision depends on the balance between risk of pulmonary embolism and that of re-bleeding.



Conclusion: Managing venous thromboembolism is a team work. Even a single episode of breathlessness in case of meningioma must be investigated promptly. Thrombolysis is not possible in all the cases and a new thrombus can develop even if patient is on anticoagulants. Use of inferior vena cava filter though controversial can prevent a major catastrophe especially in cases where thrombolysis is contraindicated.

References:

1. Rosenthal D, Wellons ED, Levitt AB, Shuler FW, O'Conner RE, Henderson VJ. Role of prophylactic temporary inferior vena cava filters placed at the ICU bedside under intravascular ultrasound guidance in patients with multiple traumas. *J.Vasc Surg.* 2004 Nov; 40(5):958-64.
2. John Chung, Richard J T Owen. Using inferior vena cava filters to prevent pulmonary embolism. *Can Fam Physician.* 2008 January; 54(1): 49-55.
3. Joels CS, Sing RF, Heniford BT. Complications of inferior vena cava filters. *Am Surg* 2003; 69: 654- 9.
4. Levitan N, Dowlati A, Remick SC, et al. Rates of initial and recurrent thromboembolic disease among patients with malignancy versus those without malignancy. *Medicine* 1999; 78:285–291.
5. Prandoni P, Lensing AW, Prins MH, et al: Residual venous thrombosis as a predictive factor of recurrent venous thromboembolism. *Ann Intern Med* 2002 137:955–960.
6. Hamilton MG, Hull RD, Pineo GF: Venous thromboembolism in neurosurgery and neurology patients: a review. *Neurosurgery*1994; 34:280–296.
7. Levi AD, Wallace MC, Bernstein M, Walter BC. Venous thromboembolism after brain surgery, a retrospective review. *Neurosurgery* 1991; 28(6): 859- 63.
8. Chan AT, Atiemo A, Diran LK, et al: Venous thromboembolism occurs frequently in patients undergoing brain tumour surgery despite prophylaxis. *J Thromb Thrombolysis*1999; 8:139–142.
9. Sawaya R, Zuccarello M, Elkalliny M, et al: Postoperative venous thromboembolism and brain tumors: Part I. Clinical profile. *J Neurooncol* 1992; 14:119–125.
10. Douketis JD, Crowther MA, Foster GA, Ginsberg JS. Does the location of thrombosis determine the risk of disease recurrence in patients with proximal deep vein thrombosis *Am J Med.* 2001; 110: 515- 519.
11. Weitz JI, Hudoba M, Massel D, et al. Clot-bound thrombin is protected from inhibition by heparin-antithrombin III but is susceptible to inactivation by antithrombin III-independent inhibitors. *J Clin Invest.* 1990; 86:385–391.
12. Ginsberg JS, Wells PS, Kearon C, Anderson D, Crowther M, Weitz JI, Bormanis J, Brill-Edwards P, Turpie AG, MacKinnon B, Gent M, Hirsh J: Sensitivity and specificity of a rapid whole-blood assay for D dimer in the diagnosis of pulmonary embolism. *Ann Intern Med* 1998; 129:1006-1011.
13. Salil H. Patel, MD and Rima Patel, PharmD. Inferior Vena Cava Filters for Recurrent Thrombosis Current Evidence *Tex Heart Inst J.* 2007; 34(2): 187–194.



14. Venous thromboembolism: reducing the risk in surgical patients. Apr 2007; Published by the National Collaborating Centre for Acute Care at The Royal College of Surgeons of England, 35-43. Lincoln's Inn Fields, London, WC2A 3PE.
15. Jon R. Cohen, M.D., Louis Grella, M.D., and Marc Citron, M.D. Greenfield Filter instead of Heparin as Primary Treatment for Deep Venous Thrombosis or Pulmonary Embolism in Patients with cancer. *Cancer* 1992; 70 (7): 1993- 1996.
16. David W, Gross WS, Colaiuta E, Gonda R, Osher D, Lanuti S. Pulmonary embolus after vena cava filter placement. *Am Surg.* 1999 Apr; 65(4):341-346.